

EP CASE REPORT

Single shot electroporation of premature ventricular contractions from the right ventricular outflow tract

Boris Schmidt *, Shaojie Chen, Shota Tohoku, Stefano Bordignon, Fabrizio Bologna, and K.R. Julian Chun

Cardioangiologisches Centrum Bethanien, AGAPLESION Markus Krankenhaus, Academic Teaching Hospital of Goethe University of Frankfurt, Wilhelm Epstein Str. 4, 60431 Frankfurt, Germany

*Corresponding author. Tel: +49-69-9450280. E-mail address: b.schmidt@ccb.de

Irreversible electroporation also referred to as pulsed field ablation is a novel non-thermal ablation modality currently used for atrial fibrillation ablation.^{1,2} By creating a high-strength bipolar electrical field across myocardial cells, the cell membrane is polarized and permeabilized resulting in cell death. The first approved device (FARAWAVE) in Europe consists of a 12-Fr catheter with five splines carrying four electrodes each that is navigated over-the-wire via a steerable sheath.³ Its shape can be changed from a basket-like pose to a flower-like pose depending on the underlying anatomy.

In this case, a 48-year-old female with symptomatic premature ventricular contractions (PVCs) with left bundle branch morphology and inferior axis despite maximally tolerated dose of bisoprolol underwent electrophysiological evaluation using conscious sedation. Surface 12-lead electrocardiogram morphology was compatible with an origin in the right ventricular outflow tract (RVOT). Diagnostic work-up including echocardiography and coronary angiography revealed no evidence of structural heart disease. Coarse conventional mapping with a decapolar diagnostic catheter confirmed earlier local activation in the RVOT compared to the left (L) VOT. The diagnostic catheter was then parked in the coronary sinus.

Via a second femoral access, a steerable sheath (FARADRIVE) was advanced to the right atrium. Using a 6F pigtail catheter a conventional guidewire was deployed in the left pulmonary artery (PA). This was used to navigate the sheath to the RVOT. Then, the 31-mm FARAWAVE ablation catheter was deployed in the RVOT in a basket

like pose (*Figure 1*). Bipolar local electrograms demonstrated local activation times preceding the QRS complex of the PVC by -22 ms (*Supplemental material online, Figure S1*). Fluoroscopically, the catheter was far away from the location of the His bundle. Pulsed field ablation was carried out using pulses of 2.5 s duration with a voltage of 1.8 kV. After the first energy application PVCs were completely abolished. The local electrogram amplitude was markedly reduced. For lesion consolidation two pairs of pulses were applied in two different basket orientations. The latter was achieved by rotating the basket by approximately 45°.

Haemostasis was achieved by a subcutaneous Z suture. No complications were observed. The procedure and fluoroscopy times were 58 and 11 min, respectively. The fluoroscopy dose was 953 μGy^2 .

Before discharge 48-h Holter monitoring showed complete abolition of PVCs. Ablation success was confirmed with a repeat 24-h Holter 2 months after the ablation.

To the best of our knowledge, this is the first description of irreversible electroporation for the clinical treatment of ventricular arrhythmias in humans.

Further research is warranted before the technology may be routinely adopted for the ablation of ventricular arrhythmias. While conceptually it may be appealing to successfully ablate focal ventricular arrhythmias with a single energy application, the current catheter design

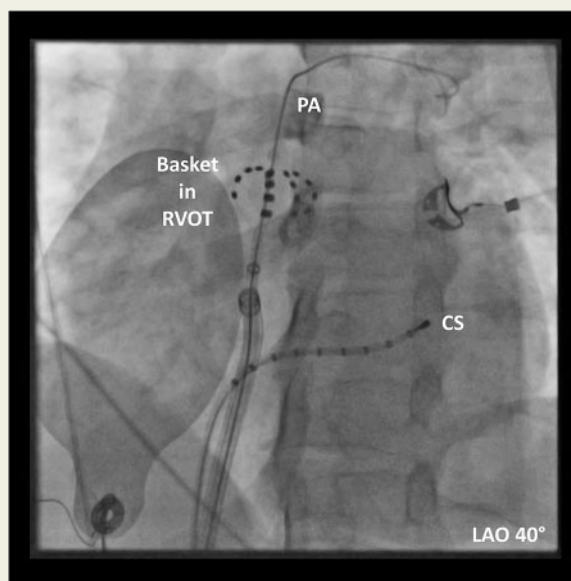


Figure 1 LAO fluoroscopy. The FARAWAVE ablation catheter is positioned in a basket pose in the RVOT. The support wire is deployed in the left PA. A multipolar diagnostic catheter was placed in the CS. CS, coronary sinus; LAO, left anterior oblique; PA, pulmonary artery; RVOT, right ventricular outflow tract.

allows only for spherical rather than focal ablation. Therefore, energy applications in the vicinity of the conduction system should be avoided. Given the pre-clinical lesion assessment, we would recommend at least 2 cm distance to the His bundle or the Tawara fascicles. Future catheter designs, however, will allow for focal ablation using electroporation.

Supplementary material

Supplementary material is available at *Europace* online.

Conflict of interest: none declared.

References

1. Reddy VY, Dukkipati SR, Neuzil P, Anic A, Petru J, Funasako M *et al*. Pulsed field ablation of paroxysmal atrial fibrillation: 1-year outcomes of IMPULSE, PEFCAT, and PEFCAT II. *JACC Clin Electrophysiol* 2021;**7**:614–27.
2. Koruth JS, Kuroki K, Iwasawa J, Viswanathan R, Brose R, Buck ED *et al*. Endocardial ventricular pulsed field ablation: a proof-of-concept preclinical evaluation. *Europace* 2020;**22**:434–9.
3. Reddy VY, Neuzil P, Koruth JS, Petru J, Funasako M, Cochet H *et al*. Pulsed field ablation for pulmonary vein isolation in atrial fibrillation. *J Am Coll Cardiol* 2019;**74**:315–26.